International Agency for Research on Cancer

World Health Organization

The 2017 WHO Classification of Tumours of Pituitary Gland

A Summary

Prof. Dr. Jean Costa Nunes, M.D., Ph.D.

Neuropatologia/Patologia/Neurologia

Rudolf Virchow
(1821-1902)

Institut für Neuropathologie, Charité Universitätsmedizin Berlin

EVOLUÇÃO

AVALIAÇÃO MORFOLÓGICA

HISTOQUÍMICA/Impregnação Argêntica

IMUNOHISTOQUÍMICA

Table 1 2017 WHO classification of tumors of the pituitary gland. Modified from WHO classification of tumors of the pituitary gland [37]

Pituitary adenomas	Somatotroph adenoma
	Lactotroph adenoma
	Thyrotroph adenoma
	Corticotroph adenoma
	Gonadotroph adenoma
	Null-cell adenoma
	Plurihormonal and double adenomas
Pituitary carcinoma	
Pituitary blastoma	
Tumors of the posterior pituitary	Pituicytoma
	Granular cell tumor of the sella
	Spindle cell oncocytoma
	Sellar ependymoma
Neuronal and paraneuronal tumors	Gangliocytoma and mixed gangliocytoma-adenoma
	Neurocytoma
	Paraganglioma
	Neuroblastoma
Craniopharyngioma	Adamantinomatous craniopharyngioma
	Papillary craniopharyngioma
Mesenchymal and stromal tumors	Meningioma
	Schwannoma
	Chordoma, NOS
	Chondroid chordoma
	"Dedifferentiated" chordoma
	Solitary fibrous tumor/hemangiopericytoma
	Grade 1 SFT/HPC
	Grade 2 SFT/HPC
	Grade 3 SFT/HPC
Hematolymphoid tumors	
Germ cell tumors	Germinoma
	Yolk sac tumor
	Embryonal carcinoma
	Choriocarcinoma

HEMATOXILINA/EOSINA (HE)

ADENOHIPÓFISE NORMAL

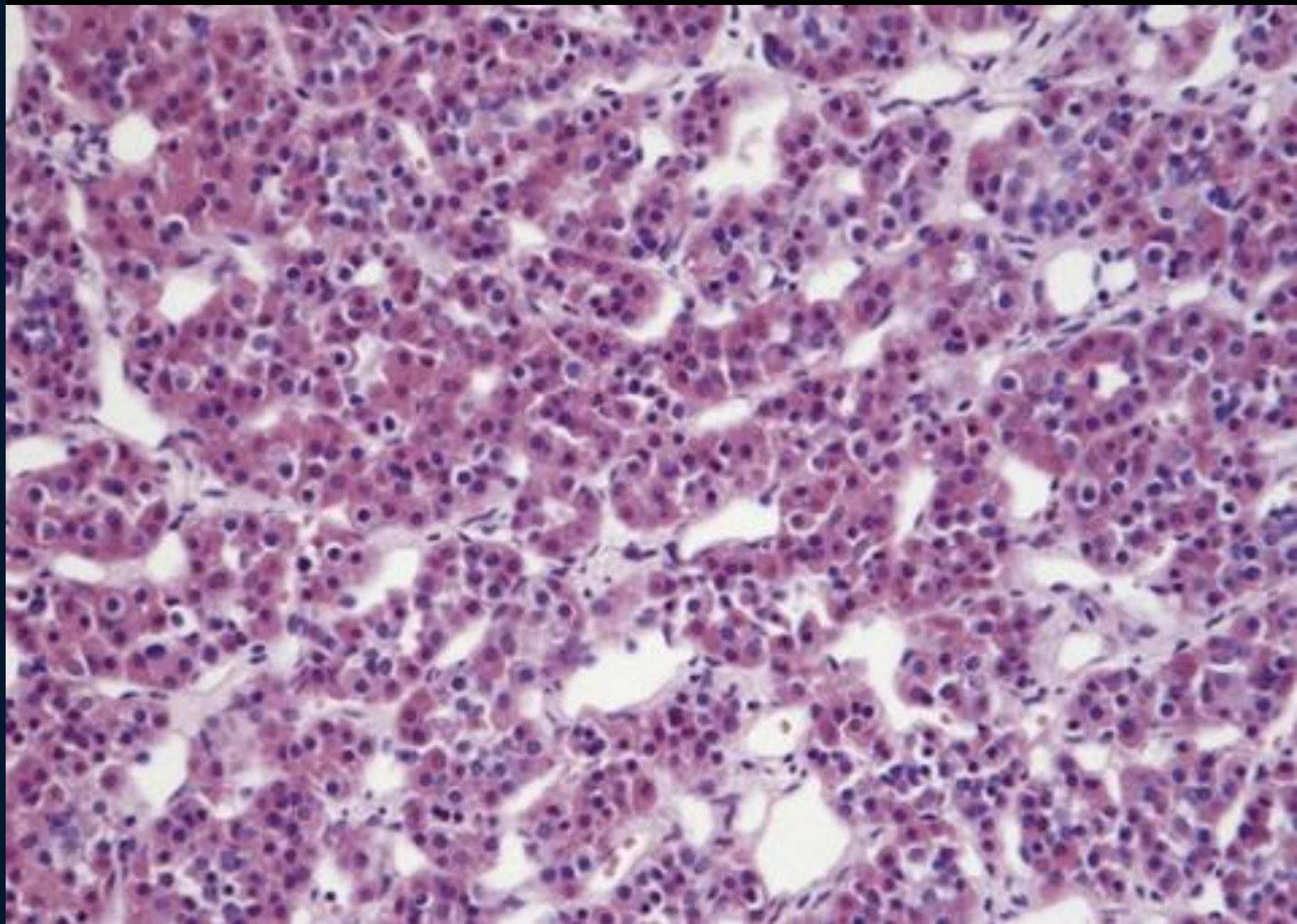

IMPREGNAÇÃO ARGÊNTICA (RETICULINA)

ADENOHIPÓFISE NORMAL

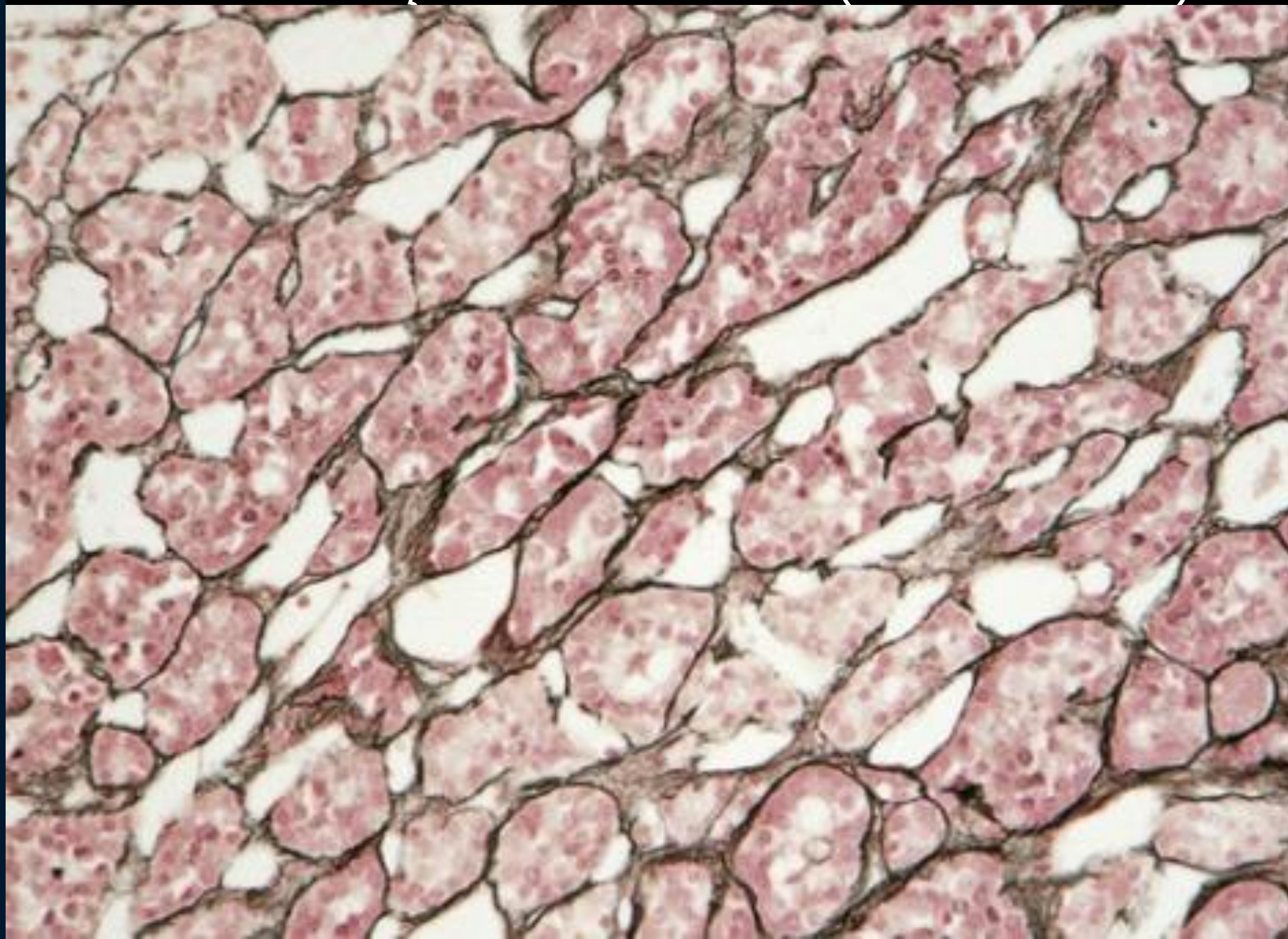

IMPREGNAÇÃO ARGÊNTICA (RETICULINA)

ADENOMA HIPOFISÁRIO

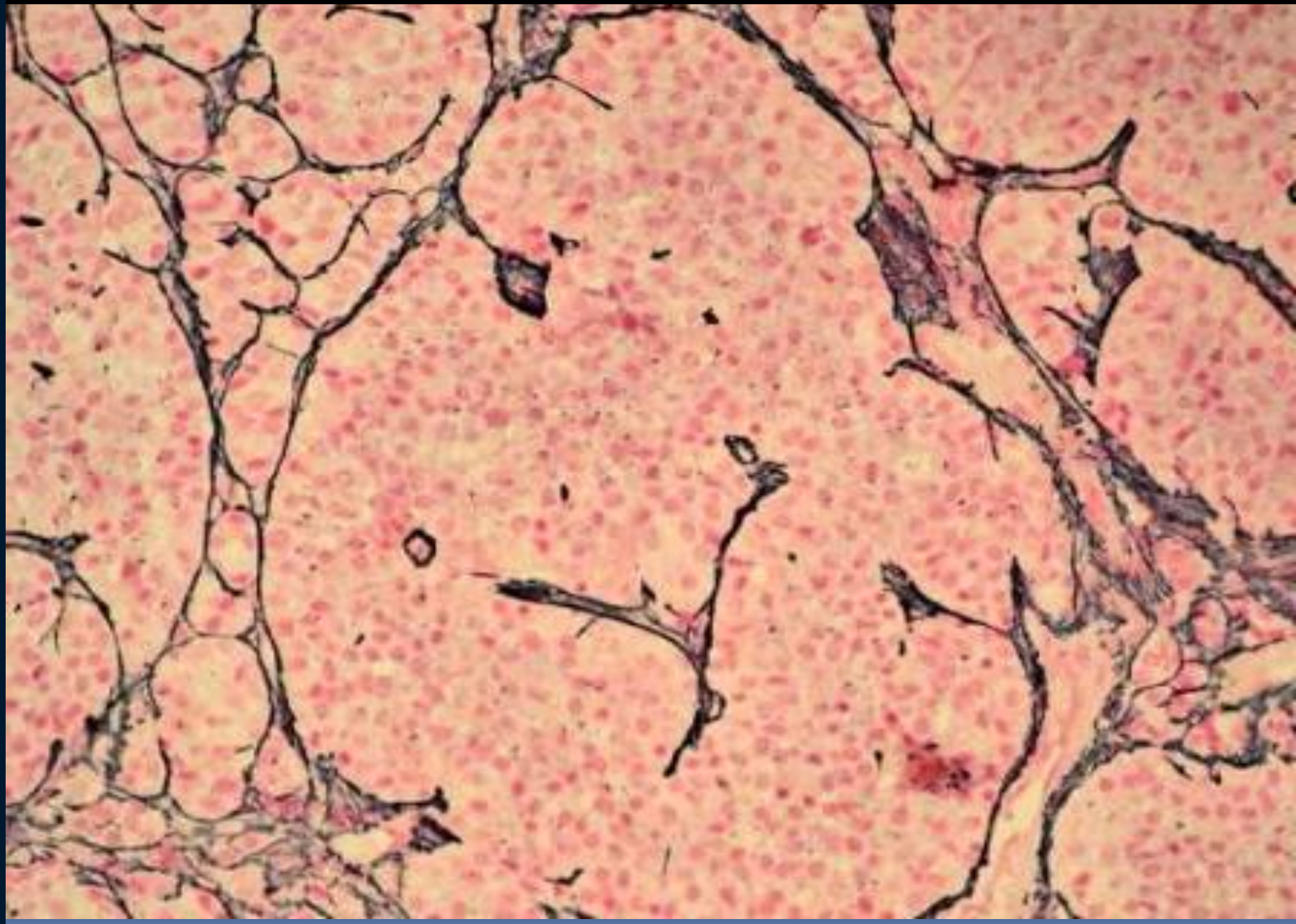

DIFERENCIAÇÃO

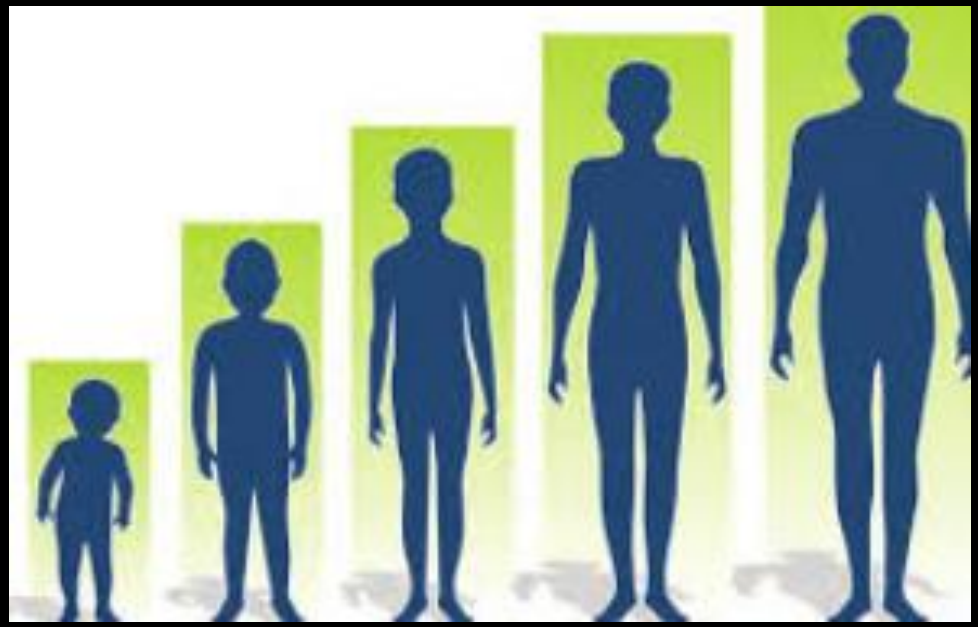

FOLHETOS EMBRIONÁRIOS

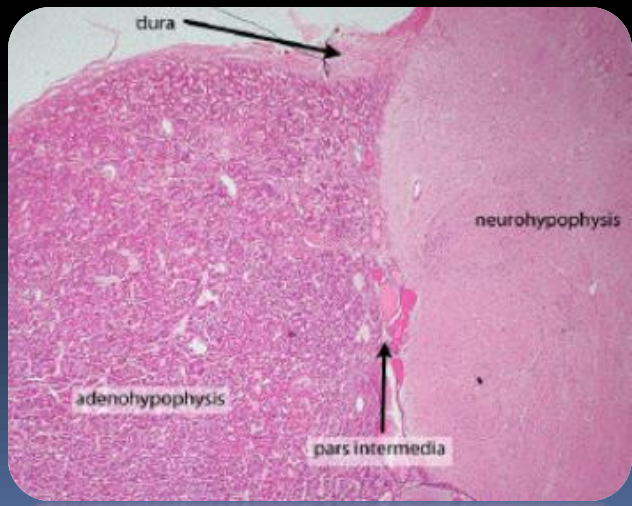

Classificação dos Adenomas Hipofisários (WHO2017)

ADENOMAS

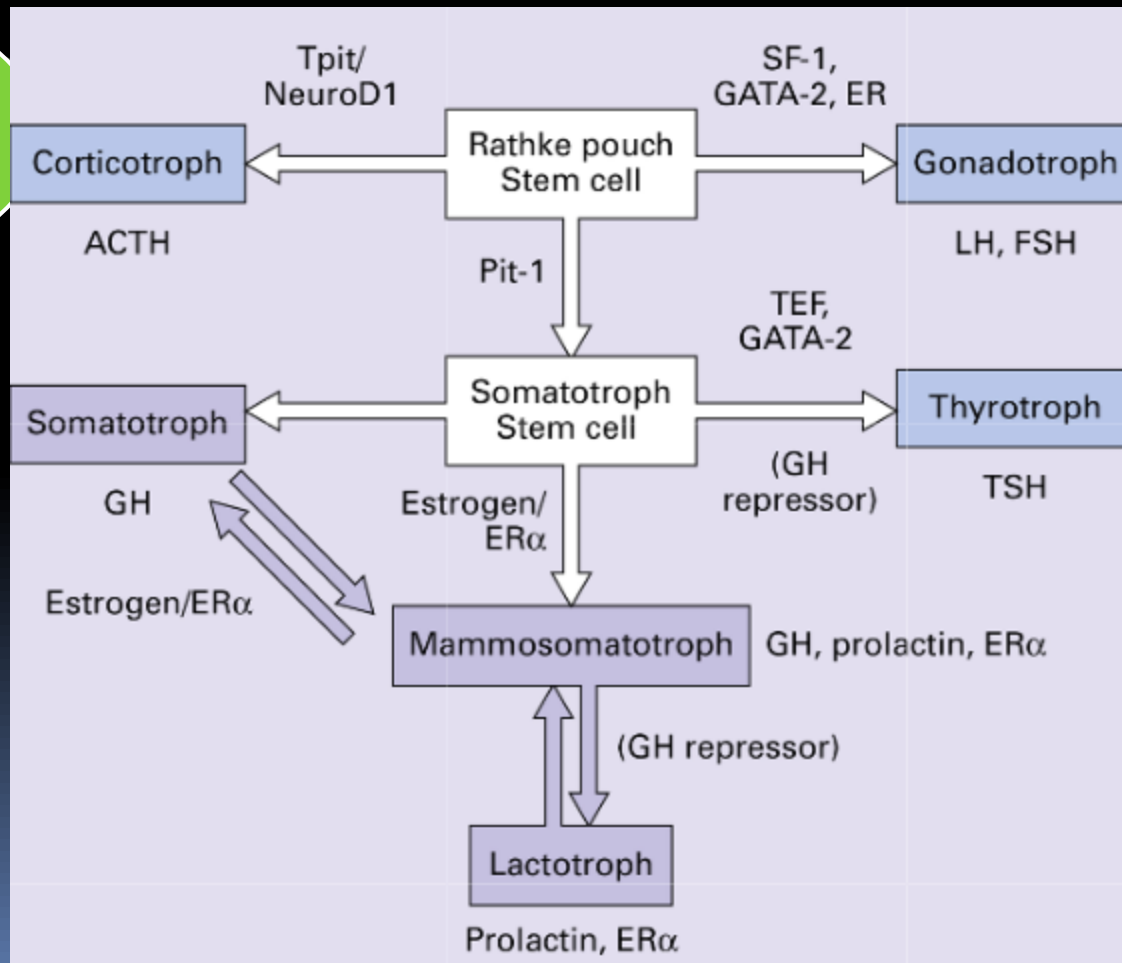

LINHAGENS DE CÉLULAS ADENOHIPOFISÁRIAS

- LINHAGEM ACIDOFÍLICA
- LINHAGEM CORTICOTRÓFICA
- LINHAGEM GONADOTRÓFICA

Classificação dos Adenomas Hipofisários

Lineage	Main transcription factors and other co-factors	Adenohypophyseal cell
Acidophilic lineage	PIT-1	Somatotrophs
	PIT-1, ERα	Lactotrophs
	PIT-1, GATA-2	Thyrotrophs
Corticotroph lineage	T-PIT	Corticotrophs
Gonadotroph lineage	SF-1; GATA-2, ERα	Gonadotrophs

Classificação dos Adenomas Hipofisários

ATUAL

ADENOMA LACTOTRÓFICO

X

ADENOMA PRODUTOR DE PROLACTINA

ESTUDO IMUNOHISTOQUÍMICO

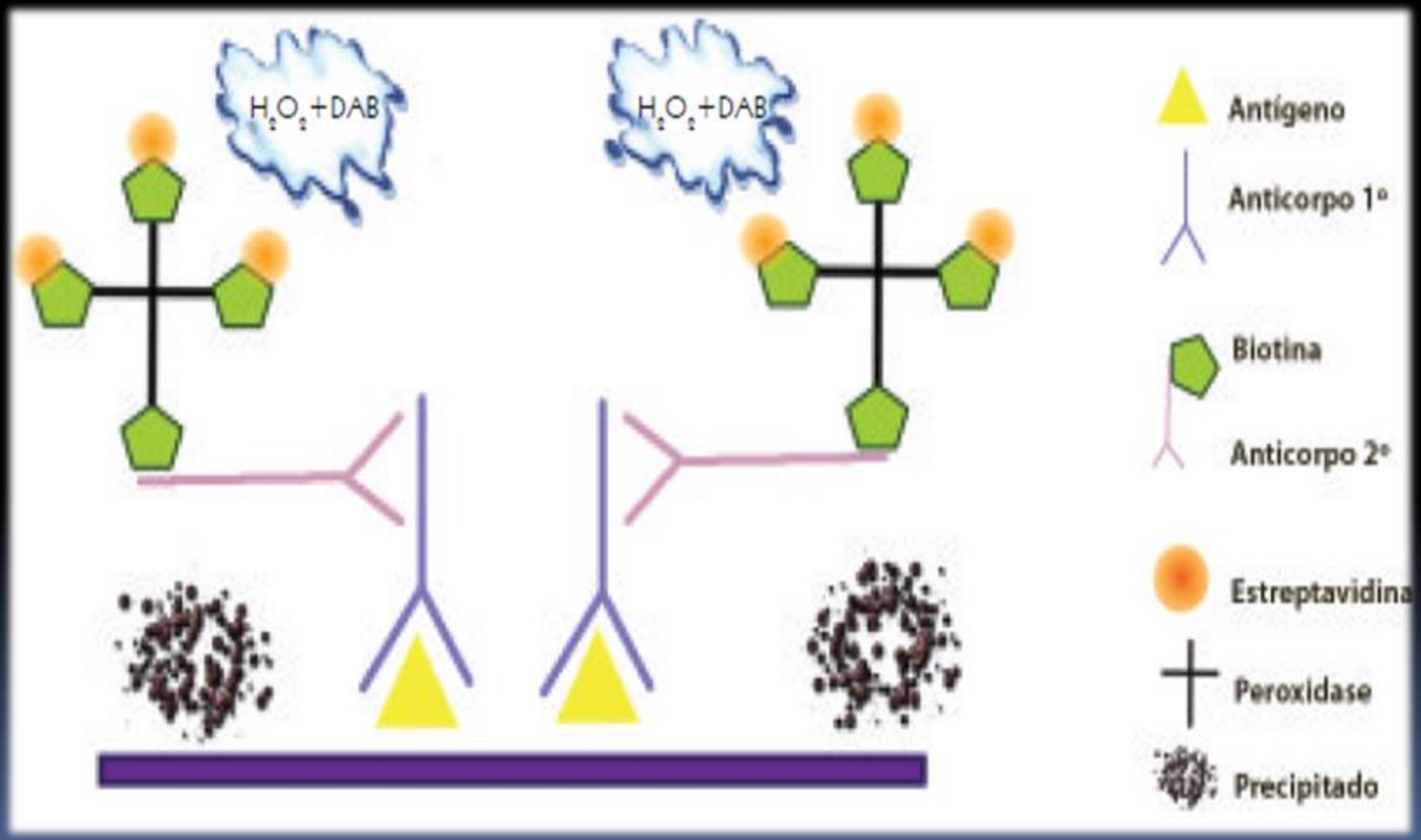

Tumours of Pituitary Gland

Classificação e Nomenclatura

Adenoma type	Morphological variants	Pituitary hormones and other immunomarkers
Somatotroph adenomas	Densely granulated adenoma[a]	GH ± PRL ± α-subunit
	Sparsely granulated adenoma	GH ± PRL, [CK]
	Mammosomatotroph adenoma	GH + PRL (in same cells) ± α-subunit
	Mixed somatotroph–lactotroph adenoma	GH + PRL (in different cells) ± α-subunit
Lactotroph adenomas	Sparsely granulated adenoma[a]	PRL
	Densely granulated adenoma	PRL
	Acidophilic stem cell adenoma	PRL, GH (focal and variable)
Thyrotroph Adenoma		β-TSH, α-subunit
Corticotroph adenomas	Densely granulated adenoma[a]	ACTH, [CK]
	Sparsely granulated adenoma	ACTH, [CK]
	Crooke's cell adenoma	ACTH, [CK]
Gonadotroph adenoma		β-FSH, β-LH, α-subunit (various combinations)
Null cell adenoma		None
Plurihormonal adenomas	Plurihormonal PIT-1 positive adenoma (previously called silent subtype 3 adenoma)	GH, PRL, β-TSH ± α-subunit
	Adenomas with unusual immunohistochemical combinations	Various combinations: ACTH/GH, ACTH/PRL

M.B. Lopes. The 2017 WHO Classification of Tumours of the Pituitary Gland : a summary. Acta Neuropathol 2017;134:521-35.

Classificação dos Adenomas Hipofisários (WHO2017)

EXEMPLO

ADENOMA SOMATOTRÓFICO

DENSAMENTE GRANULAR

ESPARSAMENTE GRANULAR

Classificação dos Adenomas Hipofisários

EXEMPLO

ADENOMA SOMATOTRÓFICO
- Densamente Granular

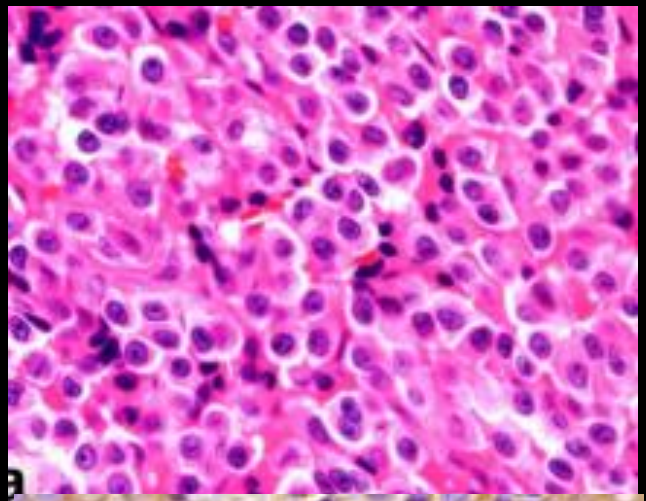

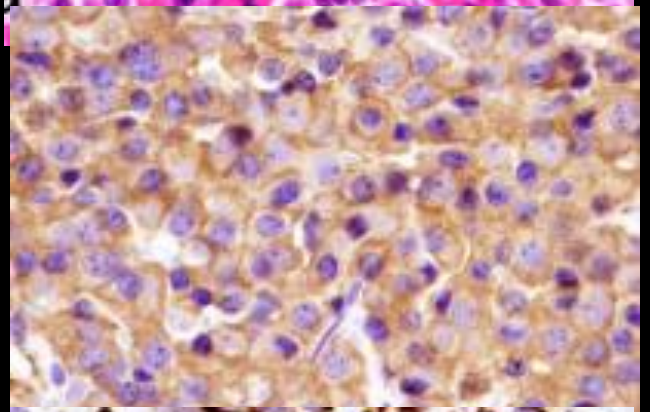

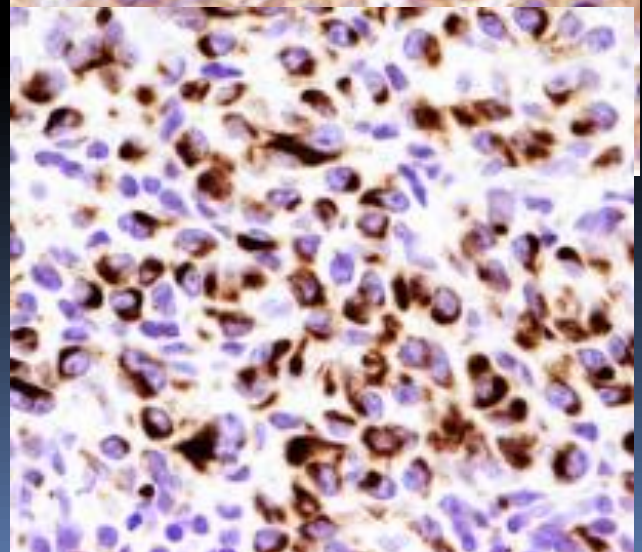

1) HE
2) GH
3) Citoqueratinas

Classificação dos Adenomas Hipofisários (WHO2017)

TERMINOLOGIA

NULL CELL ADENOMAS

SILENT ADENOMAS

DOUBLE ADENOMAS

PLURIHORMONAL ADENOMAS

-monomórficos

-plurimórficos

FREQUÊNCIA

Peptide		Percentage of total[a]
PRL		25
GH	densely granulated[b]	6
	sparsely granulated[b]	3
ACTH		12
FSH/LH		8
TSH		1
PRL + GH mammosomatotroph adenoma		2
PRL + GH acidophil stem cell adenoma		2
PRL + GH mixed cell adenoma		5
GH + TSH ± α-subunit ± PRL and FSH + LH ± TSH ± α-subunit ± GH ± PRL		10
Null-cell adenoma		25
Others		1

Ellison et al. Neuropathology Textbook

Tumores Hipofisários

GRADUAÇÃO

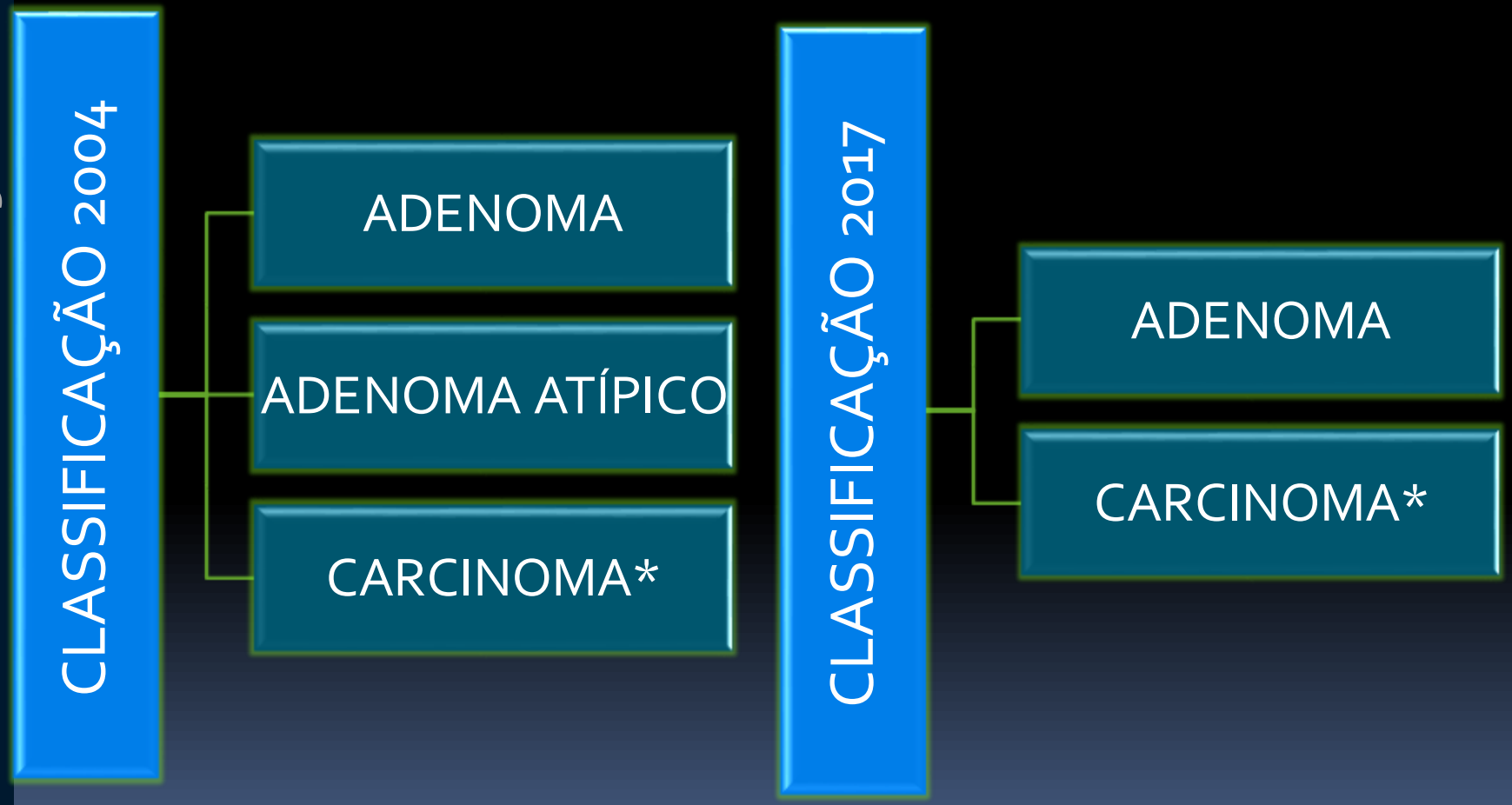

*Manutenção dos Critérios Diagnósticos

Adenomas – Probabilidade de recorrência

Low probability for recurrence	High probability for recurrence	Malignant (metastatic) tumor
Pituitary adenoma	Adenomas with elevated proliferative activity	Pituitary carcinoma
	Special subtypes (variants) of adenomas:	
	Sparsely granulated somatotroph adenoma	
	Lactotroph adenoma in men	
	Silent corticotroph adenoma	
	Crooke cell adenoma	
	Plurihormonal PIT-1 positive adenoma	

M.B. Lopes. The 2017 WHO Classification of Tumours of the Pituitary Gland : a summary. Acta Neuropathol 2017;134:521-35.

OBRIGADO!

TELEFONES:

- ✓ FIXO: (48) 3091-5611
- ✓ CELULAR: (48) 9697-1302

EMAIL:

- ✓ neurodiagnostic@neurodiagnosticbrasil.com
- ✓ jeanmedic@neurodiagnosticbrasil.com

SITE:

- ✓ www.neurodiagnosticbrasil.com